

PATIENT MEDICAL HISTORY

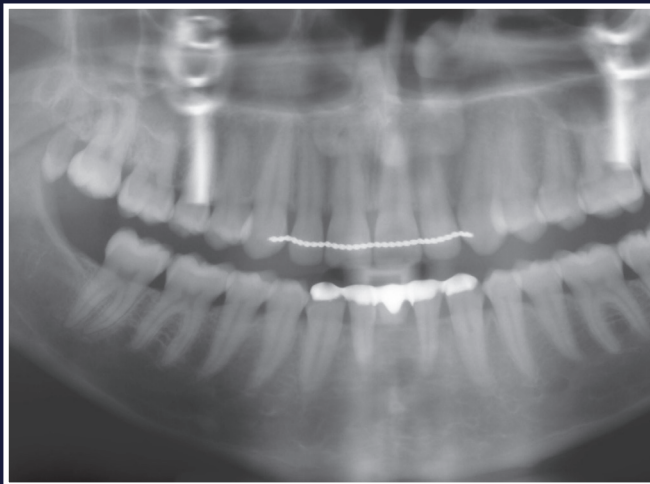
Female
23 years old
Non-smoker

Agenetic lower incisors. Earlier orthodontic treatment closed the gap to one incisor and was closed with a Maryland bridge. The patient was told by two implantologists, because of the lack of bone, putting an implant in was impossible. The incisors never grown, so there was 1mm narrow ridge lingual, but there was ample mandibular bone, 4mm lower.

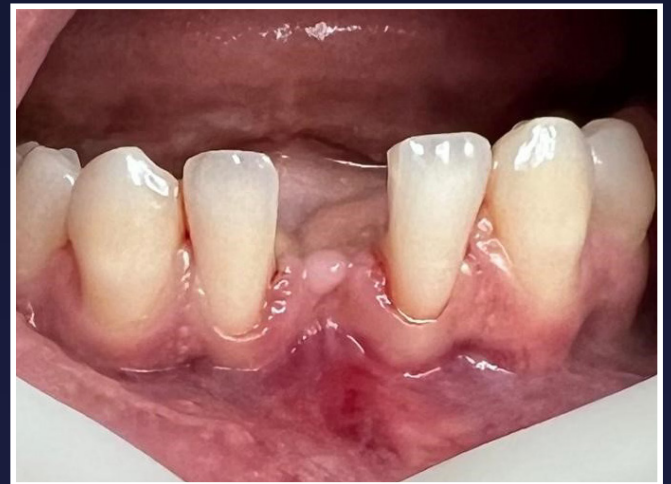Case from Dr Willem Baas,
Netherlands



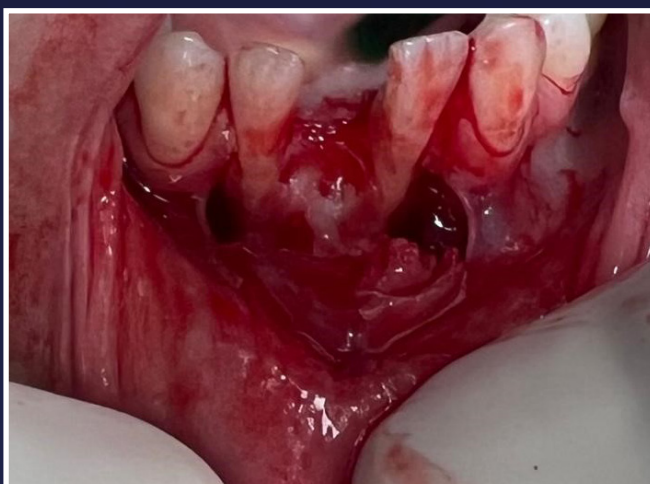 Dr Willem Baas



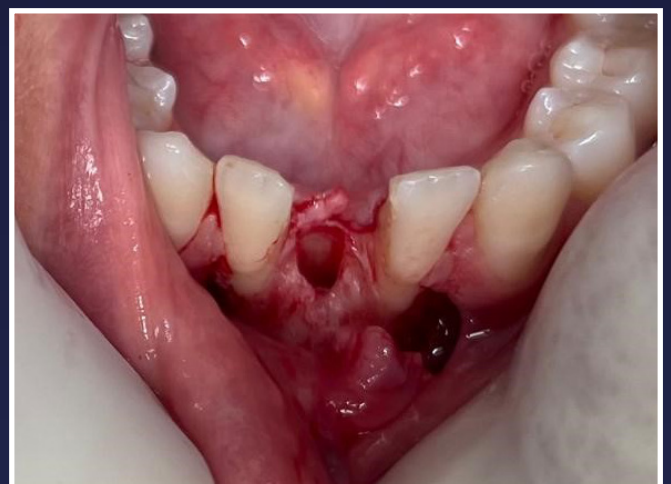1. Pre-op radiograph



2. Initial situation

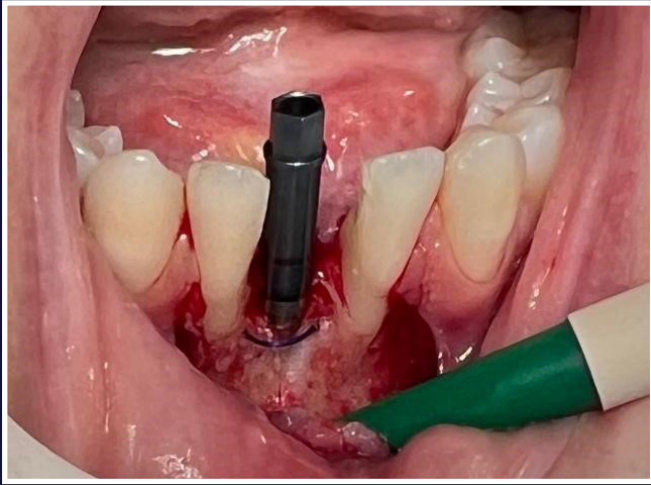


3. Flap raised

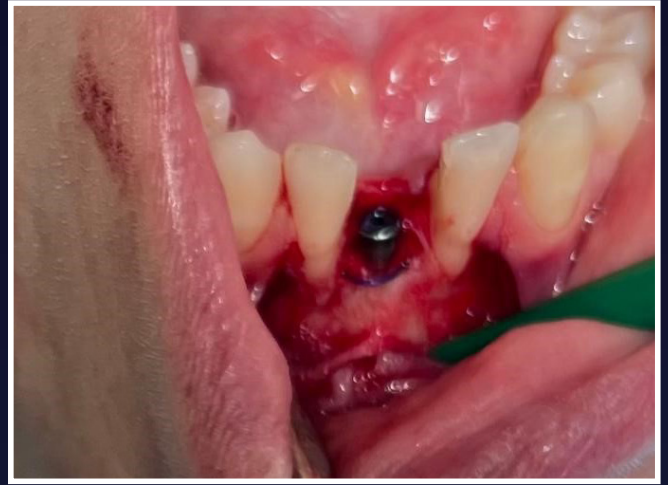

4. Site degranulated ready for implant placement

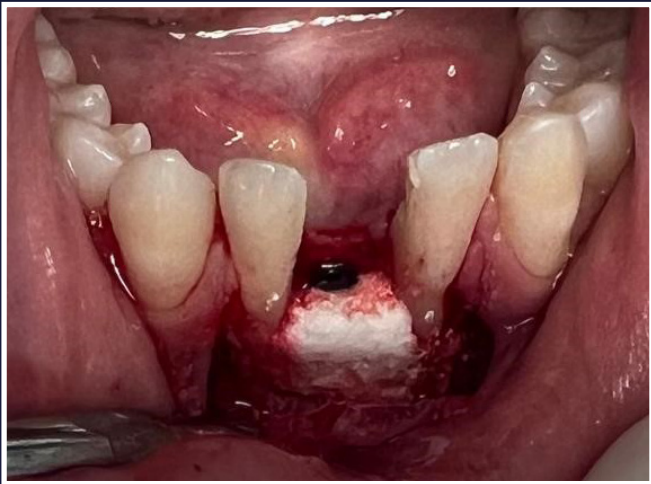Lower Anterior Delayed Placement



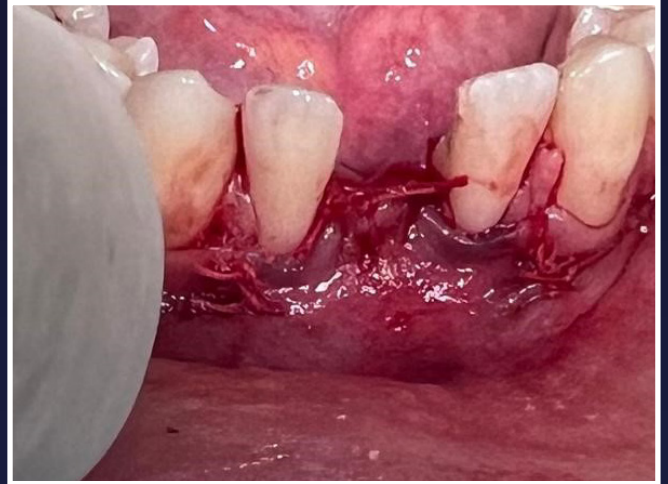
5. Implant and PDS 2.0 suture tenting technique used to augment bone horizontally



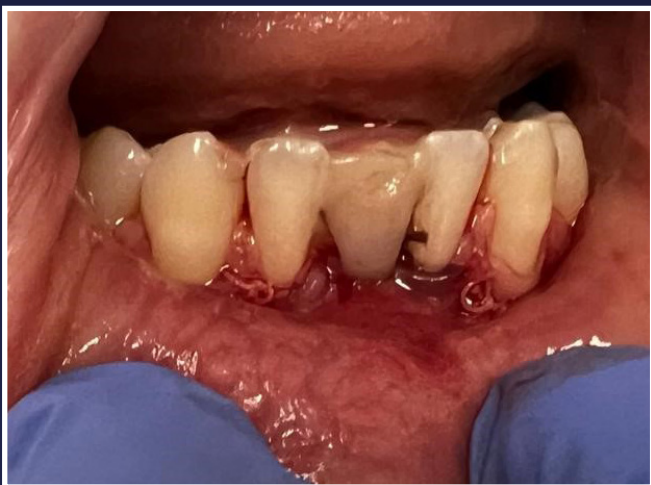6. Cover screw



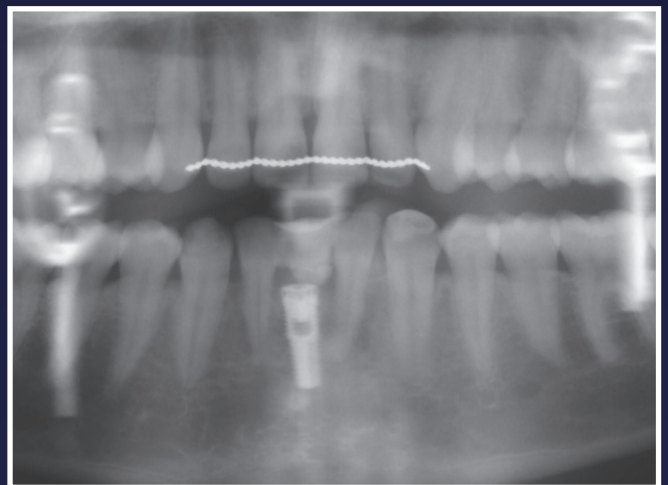
7. EthOss® bone grafting material placed



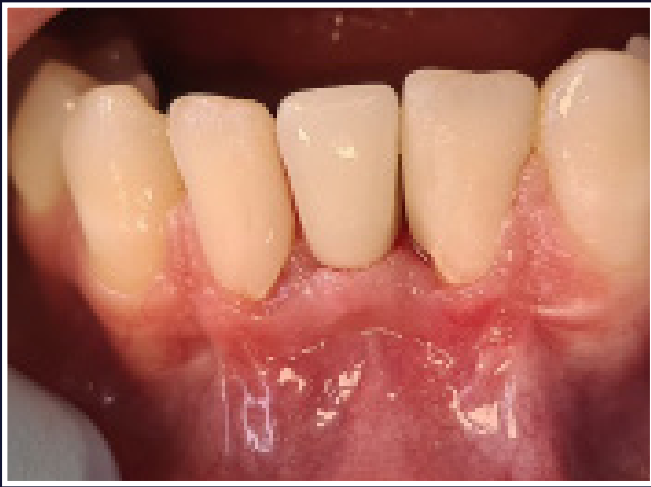8. Sutured closed



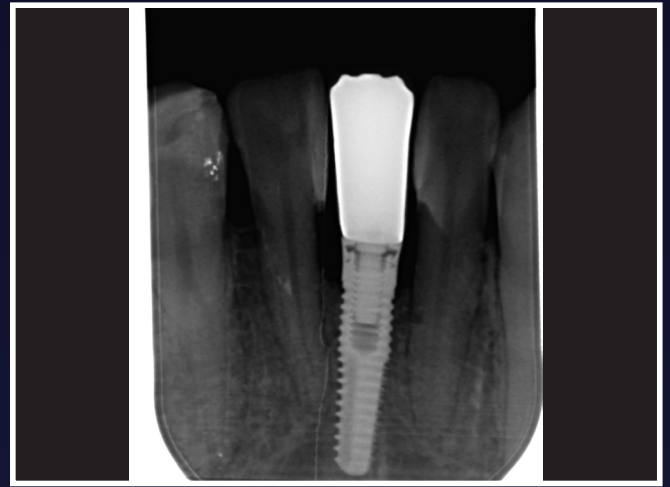
9. Provisional restoration



10. Post-op radiograph



11. 5 months post placement - final restoration



12. Radiograph 5 months post placement