

PATIENT MEDICAL HISTORY

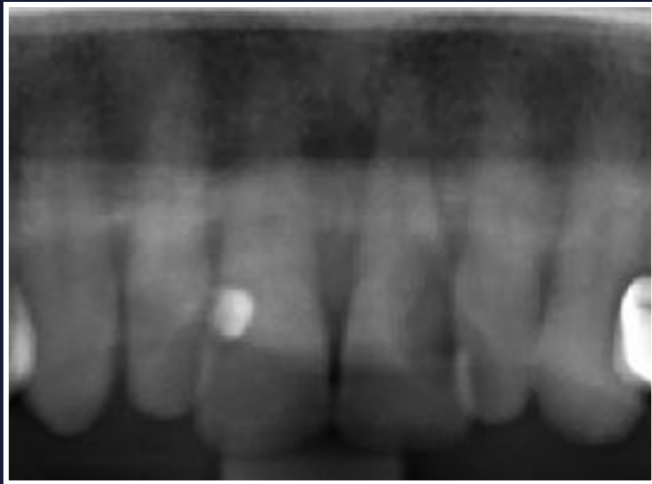
Female
69 years old
Non-smoker
Type 2 diabetic

Extraction - a month of waiting - implants, bone regeneration and immediate loading - three months of waiting - impression and delivery of monolithic crowns

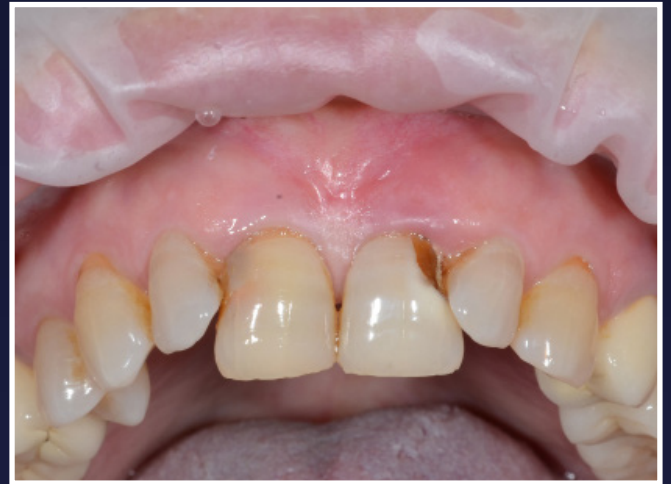Case from Dr Dario Tuscano,
Italy



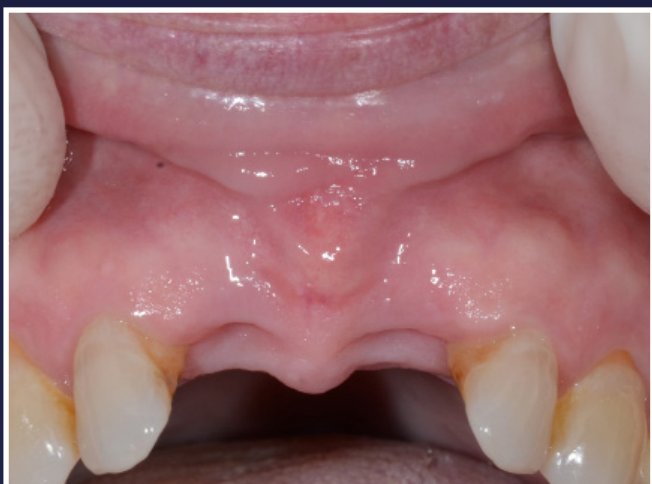 Dr Dario Tuscano



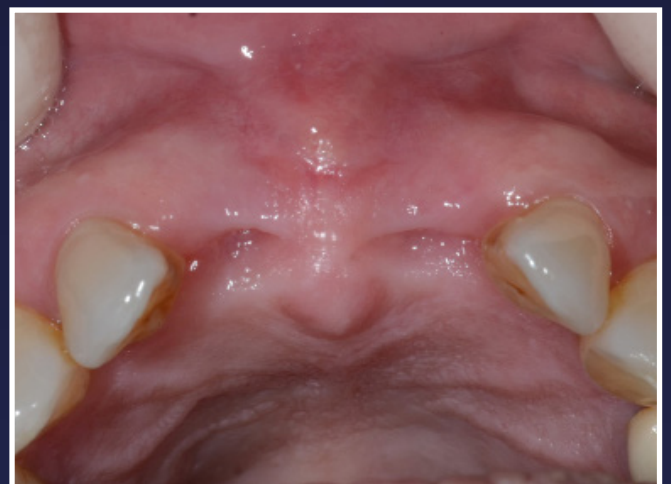1. Initial radiograph



2. Front view

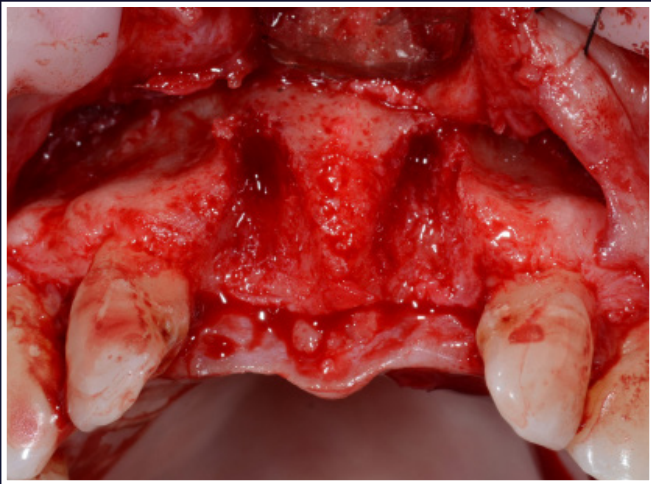


3. Front view one month post extraction

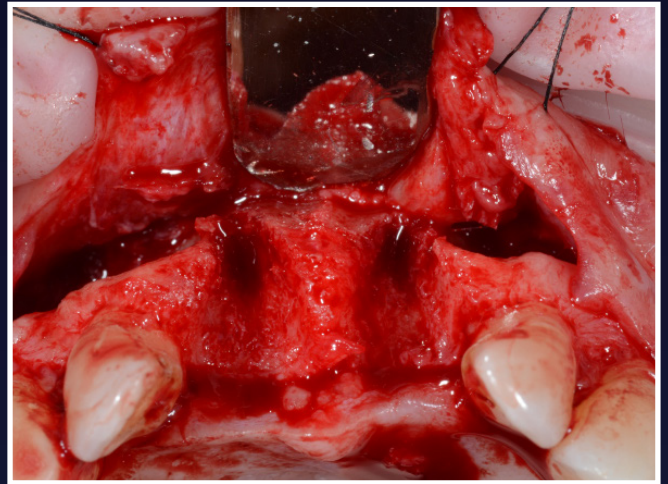


4. Occlusal photo one month post extraction

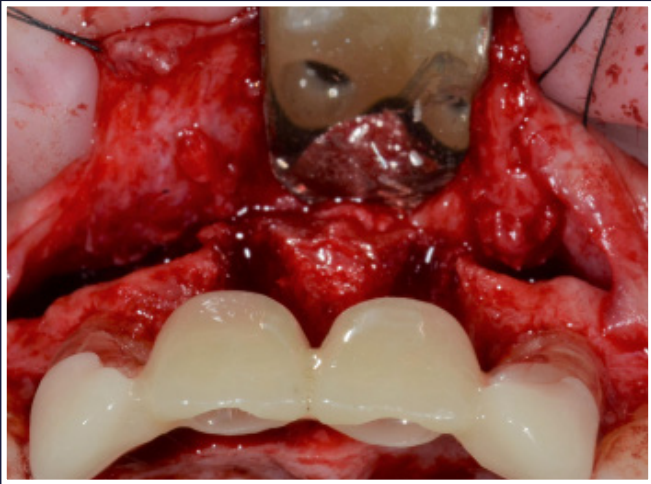
Upper Anterior Early-Delayed Placement with Immediate Loading



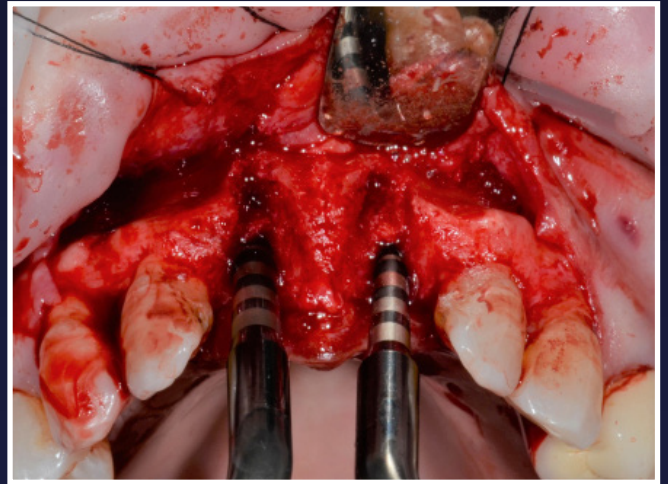
5. Frontal view after flap elevation



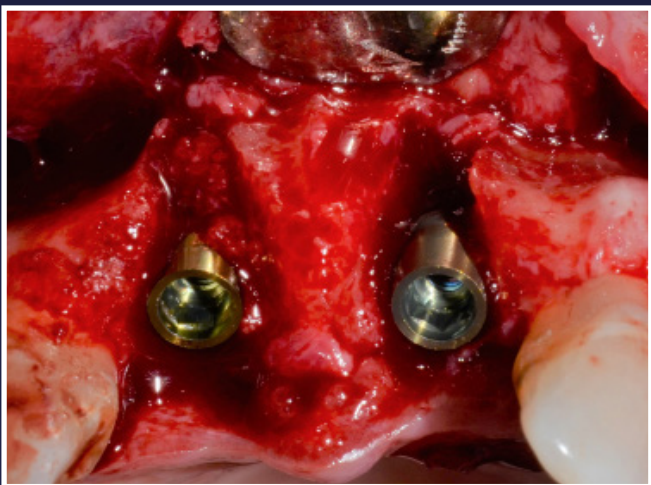
6. Occlusal view after flap elevation



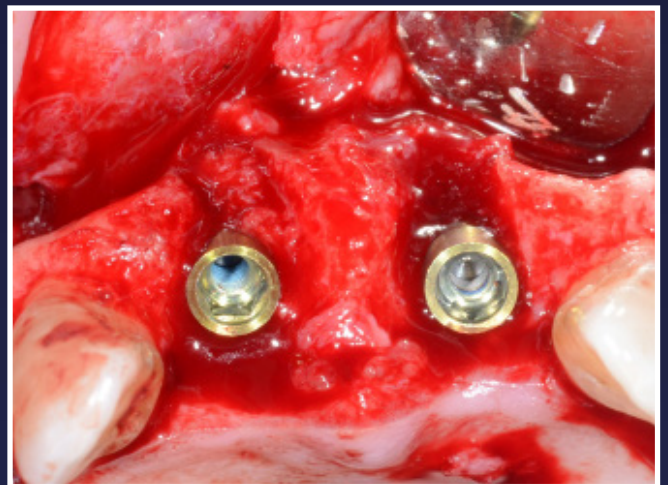
7. Template in position



8. Osteocondensation with magnetodynamic tools

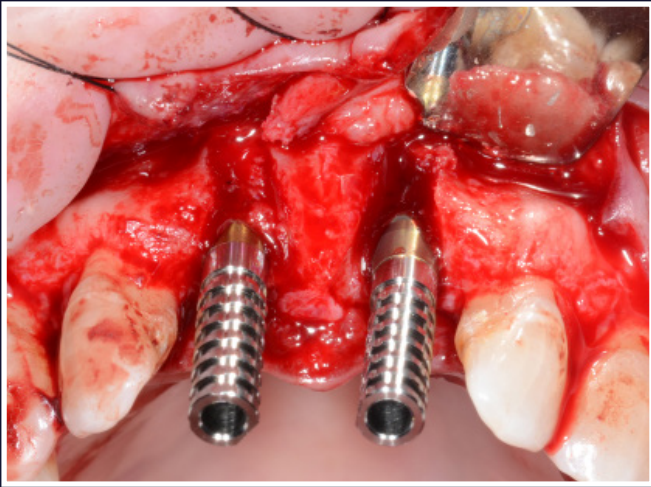


9. Implants inserted

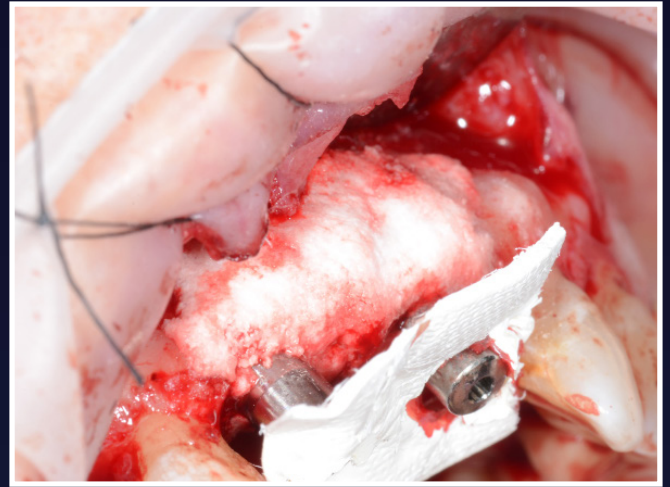


10. Implants inserted - occlusal view

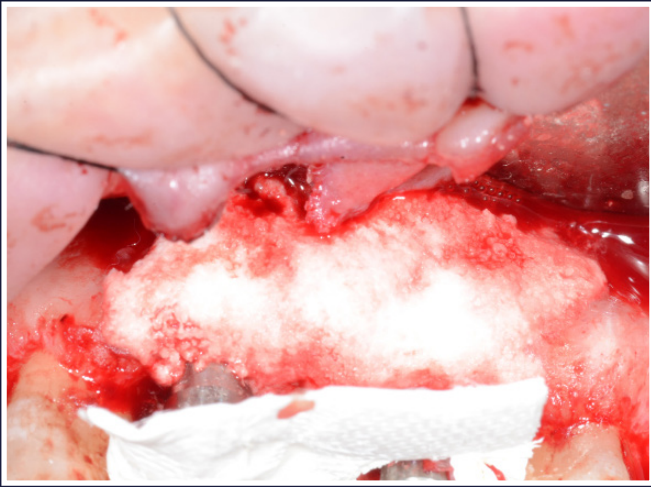
Upper Anterior Early-Delayed Placement with Immediate Loading



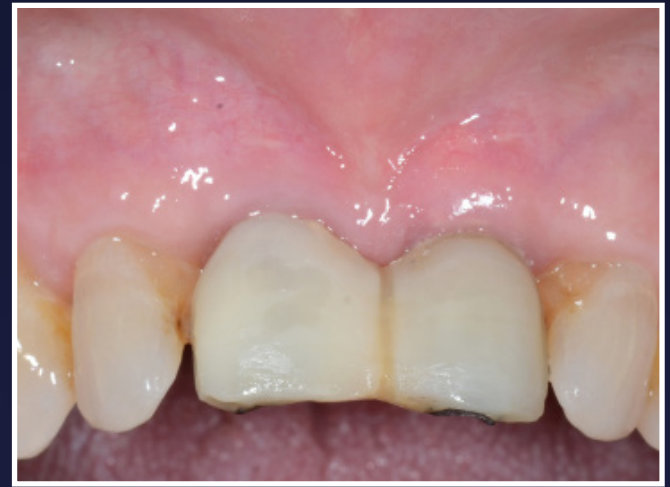11. Temporary abutments



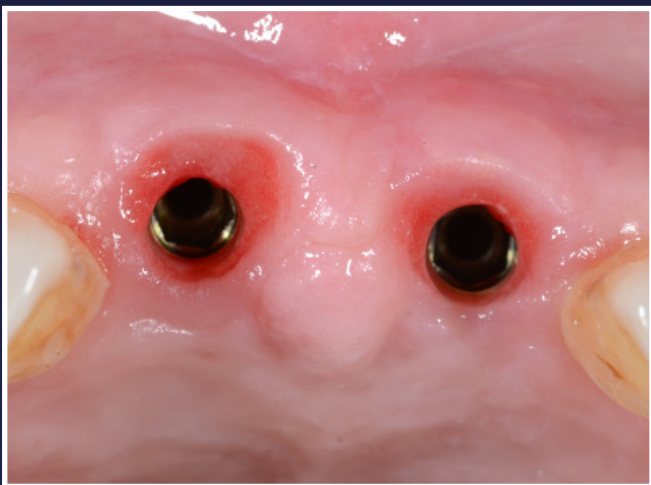
12. Bone regeneration - EthOss® bone grafting material placed



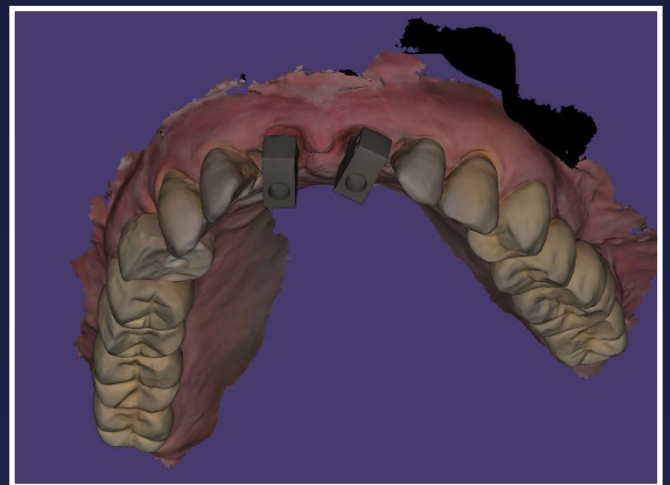
13. Collagen sponge around the emergences



14. Three months post bone regeneration

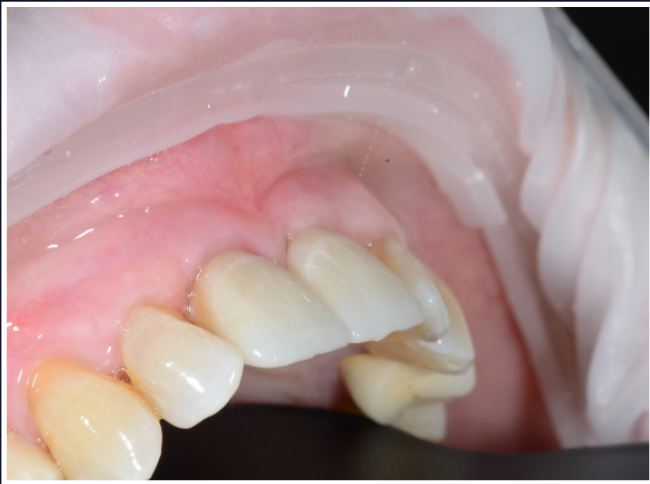

15. Occlusal view

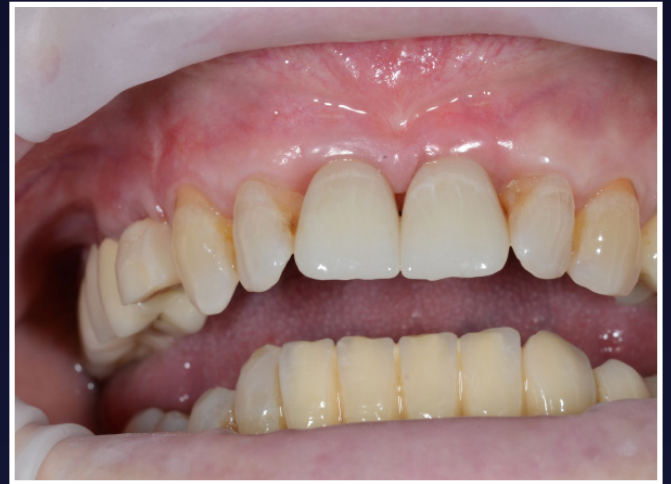

16. Digital impression

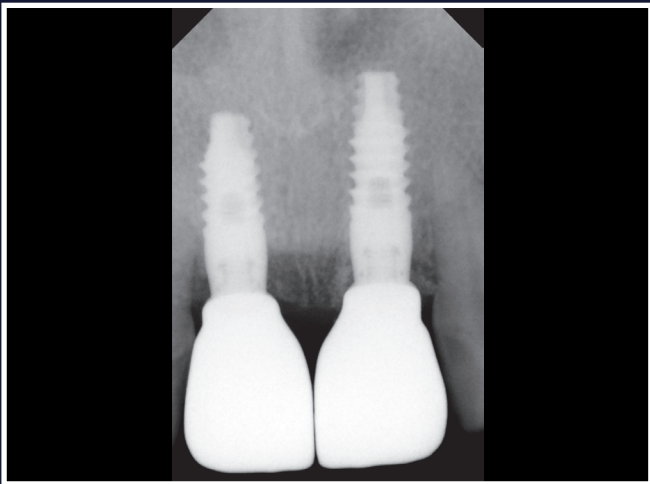
Upper Anterior Early-Delayed Placement with Immediate Loading



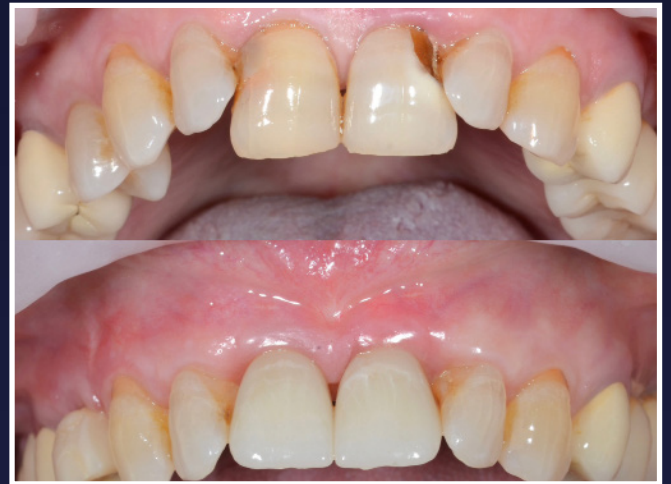17. Delivery of monolithic crowns



18. Delivery of monolithic crowns



19. Radiograph on delivery



20. Before and after